

PG Forum

REHAB CHALLENGES

A 26 years old male patient presented to PMR OPD with spastic quadriplegia and immobility since last 2 years due to a compressive myelopathy after a road traffic accident. He was treated by neurosurgeons for initial few months and became haemodynamically stable within few days though there is no significant neurological recovery over the months. Thereafter patient was poorly managed mainly at home with little bit of unsupervised physiotherapy.

When we examined the patient in our indoor we found around grade 3 spasticity in ankle planti-flexors and hamstrings bilaterally, that was managed by stretching, medication and chemical neurolysis followed by tone inhibiting orthosis and gait training. He achieved reasonable indoor independent mobility with the above indoor management.

But patient was struggling to manage his ADL due to poor ROM of both elbows though hand function improved little bit with conservative management (Fig 1). X-ray (Fig 2) of both elbow joint picked up significant heterotrophic ossification bilaterally limiting his elbow movement. Further investigation like CT scan of elbow (Fig 3) also confirmed heterotrophic ossification with very close proximity to elbow joint.

Now the patient is very much keen to go back to his normal job which requires good amount of upper limb function. Please opine regarding further rehabilitative management of this young gentleman.



Fig 1

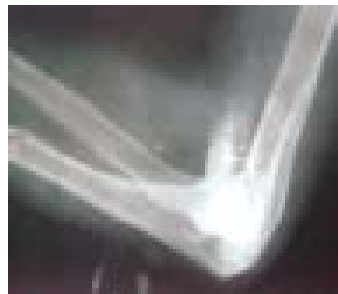


Fig 2

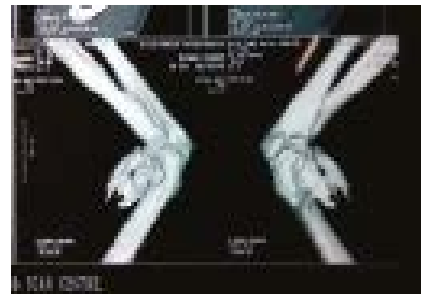

Fig 3

Medical Philately

1981 International Year of Disabled People social integration



Country	Singapore
Date	1981
Disability	Crutches
Meta	philately, stamps, digital disability, theme, imagery of disability on postage stamps, outside centre, crutches, integration, friends, social integration
Number	SG408
Theme	Integration International Year of Disabled People