

Missed Opportunity for Thrombolysis in a Patient of Massive MCA Territory Stroke

Pramanik R

A 45-year old male presented to PMR OPD with left sided complete hemiplegia (Day 3) due to stroke. Then he was admitted in PMR Indoor for neurorehabilitation. On initial evaluation he was haemodynamically stable. Motor power of his left upper limb and lower limb was 0/5. He was on catheter and IV fluid on the day of admission. When we reviewed the CT scan of his brain on Day 1 of his presentation we saw a right MCA thrombus (Fig 1). Unfortunately nobody sent the patient for thrombolysis. Eventually the patient landed up to PMR OPD for further rehabilitative management for dense hemiplegia. This was well corroborated by a repeat CT scan done in our ward

which picked up a massive right MCA Infarct (Fig 2)

Over next 3 weeks patient was treated with all forms of physiatric management. On 4th week his FIM score improved from 30/126 to 94/126. Patient was still dependent for his mobility (Fig 3) and toilet care. Muscle power improved to only grade 2/5. Then the patient was discharged home and advised to carry on supervised therapy at home.

Hence it was unfortunate for the patient to carry on his daily life with some amount of expected residual disability which possibly might be well prevented by a proper timely referral for neurothrombolysis.

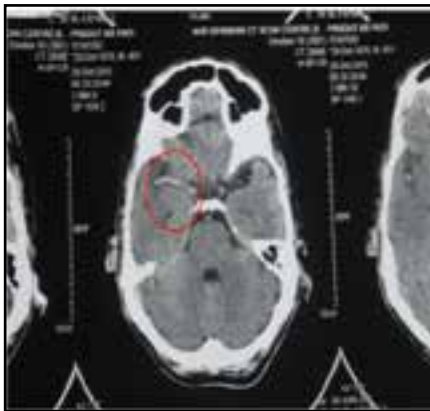


Fig 1

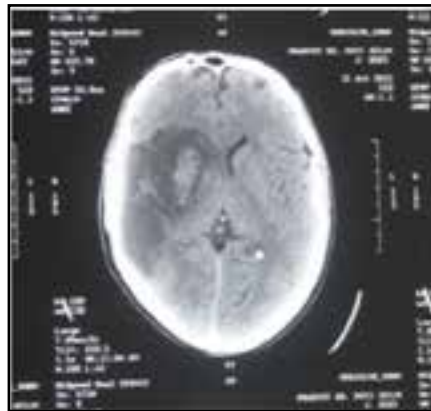


Fig 2

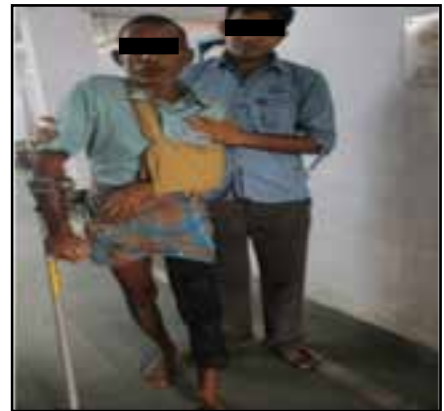

Fig 3

Authors' affiliation:

MD, MRCP (UK), Associate Professor, PMR, IPGME&R, Kolkata

Cite as:

Pramanik R. Missed Opportunity For Thrombolysis In A Patient of Massive MCA Territory Stroke. IJPMR, September 2015; Vol 26(3) :85