

Pictorial CME

Normal Pressure Hydrocephalus Presented with Confusion and Retropulsion

Pramanik R

An elderly lady with multiple comorbidities like hypertension, diabetes and dyslipidemia with past history of stroke presented to us in our OPD with gradually progressive confusion, minimal memory disturbances and loss of balance over a period of 6 months. Her son complained about her slowness of movement, lack of initiation and gradual stooping posture. On thorough clinical examination in indoor we didn't find any significant rigidity or tremor in her extremity, her postural blood pressure was absolutely fine but she had a definite retropulsion along with depression. On close questioning she gave a history of increased frequency and few episodes of incontinence in last 15 days.

Considering the above clinical picture we sent the urine and blood samples and found out that she had leucocytosis with increased inflammatory markers, and

her urine culture revealed E.coli infection with a colony count of 107. The patient was started on antibiotics and the patient's confusion decreased (MMSE from 20 to 25), but the patient still had the presenting symptoms. This prompted us to do a MRI brain to rule out dementia due to multi-infarct state. Mean while the patients gait pattern and walking showed signs of improvement after non pharmacological management like balance and gait training, strengthening of the lower limbs.

MRI (fig 1 & 2) showed no definite hydrocephalus but Evans index of 32 (radiological fulfillment of NPH), a CSF tap was scheduled to look for opening pressure and it was 270 mm of water, so a therapeutic drainage of 30 ml was done. Following this the patients gait pattern as well as walking speed improved (10 meter walking time from 15 s to 12 s) and MMSE improved to 28 from 25.

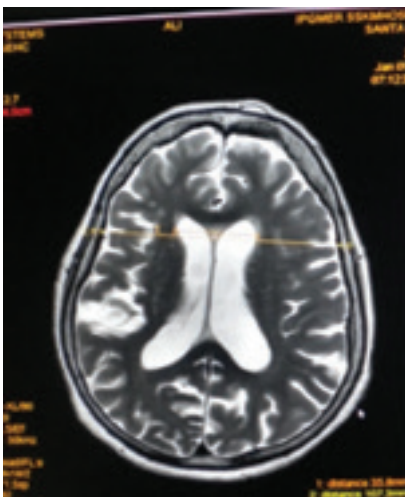


Fig 1

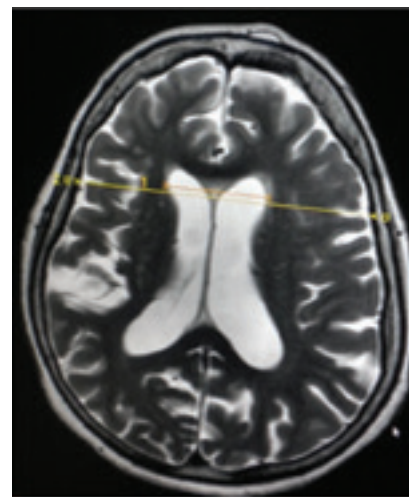


Fig 2

Authors' affiliation:

MD, MRCP (UK), Associate Professor, PMR, IPGME&R, Kolkata

Cite as:

Pramanik R. Missed Opportunity For Thrombolysis In A Patient of Massive MCA Territory Stroke. IJPMR, December 2015; Vol 26(4) :122