

## Absent radial artery in Cavanagh Syndrome

Pramanik R

**A**n young male patient presented to PMR OPD with difficulty to perform his ADL and regular jobs due to weakness of both hands. He was also suffering from wasting of bilateral thenar muscles of his hand from his childhood days. The weakness was gradually increasing day by day. Now a day it is becoming very difficult for him to do his job as a manual laborer. That's why he came to receive proper treatment in a tertiary rehabilitation center.

On examination there is bilateral thenar muscle wasting (Fig 1) and weakness of muscle power of thumb (grade 3/5) bilaterally without any sensory deficit. This lean and thin young male with mild wasting of facial muscles was not suffering from any dysphagia or dysarthria.

There was no myotonia on percussion in his thenar muscles or tongue. His phalens and tinnel signs were negative for carpal tunnel syndrome.

Interestingly he had absent radial artery pulsation on right hand and feeble pulsation on left hand. That's why a Doppler ultrasound (fig 2) was planned for his upper limb arterial system which showed complete absence of radial artery in right side and poorly visible artery in left side. X Ray of his hands did not show any absence of radius in either side. His cardio vascular system was absolutely normal on auscultation and echo cardiography. Hence the case was concluded as atypical presentation of Cavanagh Syndrome with absent radial artery.

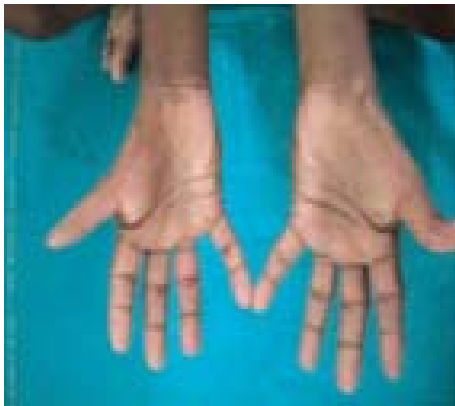

Fig 1

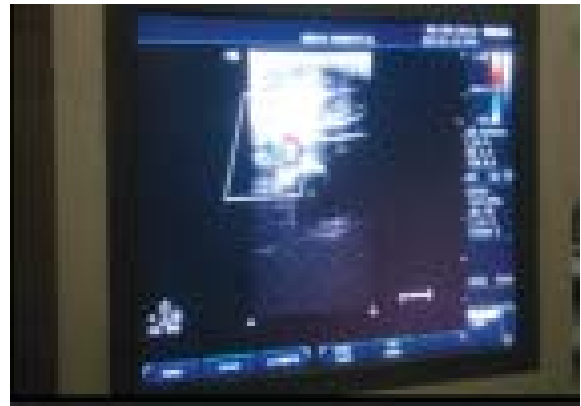


Fig 2

*Authors' affiliation:*

MD, MRCP (UK), Associate Professor, PMR, IPGME&R, Kolkata

*Cite as:*

Pramanik R. Absent radial artery in Cavanagh Syndrome. IJPMR, June 2016; Vol 27(2) :61