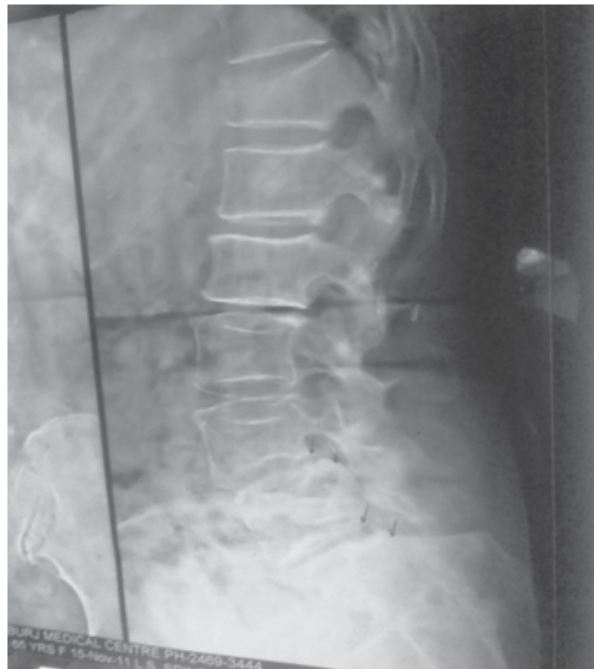


REHAB CHALLENGES

A sixty-six-year lady presented to department of PMR with severe non-inflammatory backache. On clinical examination VAS score of pain was 7 out of 10 and step sign was positive. Initially she was put on NSAID, local superficial heat and static group of spinal exercise regimen. On routine investigations spondylolisthesis of L4 over L5 was quite obvious on x-ray.



X ray picture

Interestingly it was noticed that there were few collapsed vertebrae in lower dorsal region. In routine haemogram ESR was 26mm and haemoglobin was 12.3g/dl. Subsequently DEXA- Scan of her spine showed a T score of -3.2g/dl. Her back pain was controlled by the medications and initial rehabilitation regimen.

Please opine regarding further exercise regimen and bracing options for this lady?