

Synovial Chondromatosis Misdiagnosed As OA Knee

R Pramanik¹, D K Khatua²

A 52-year old lady presented to PMR outpatient department with knee pain and swelling for last two months. At the time of first visit VAS score of pain was

7 out of 10. There was moderate tenderness on joint lines and significant effusion of her right knee joint (Figs 1 & 2).

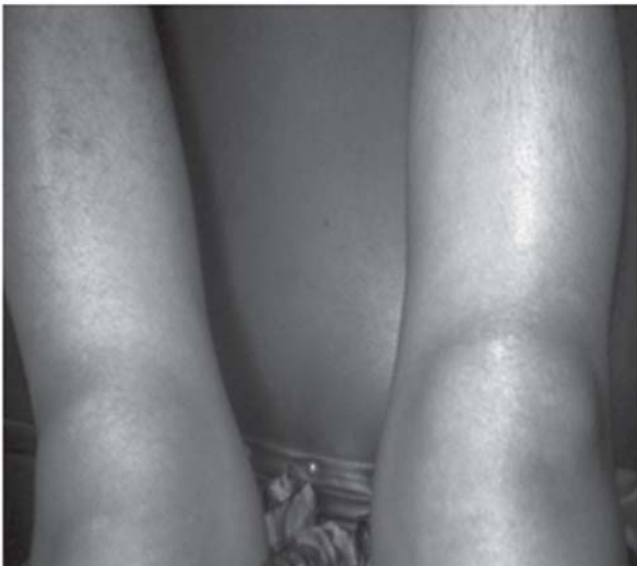

Fig: 1

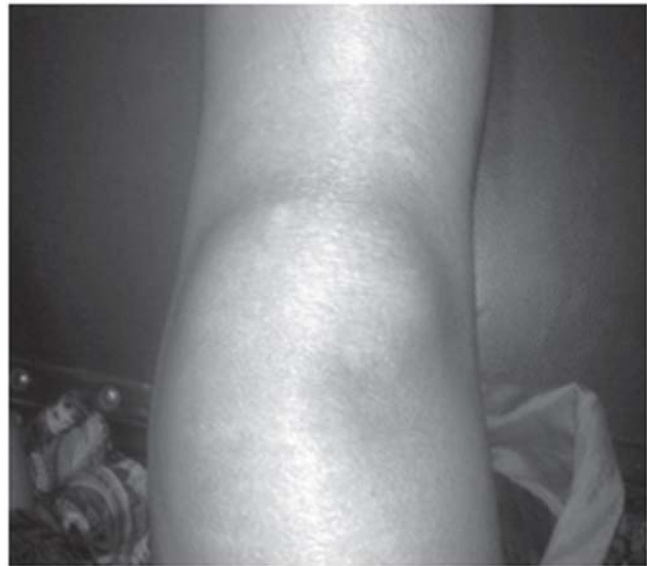

Fig: 2

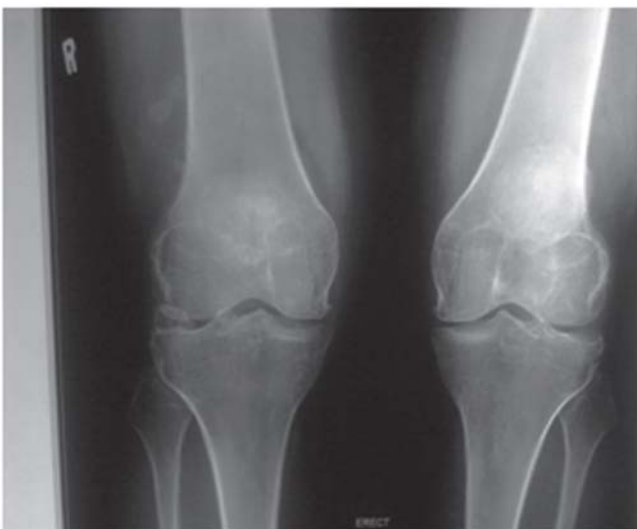

Fig: 3

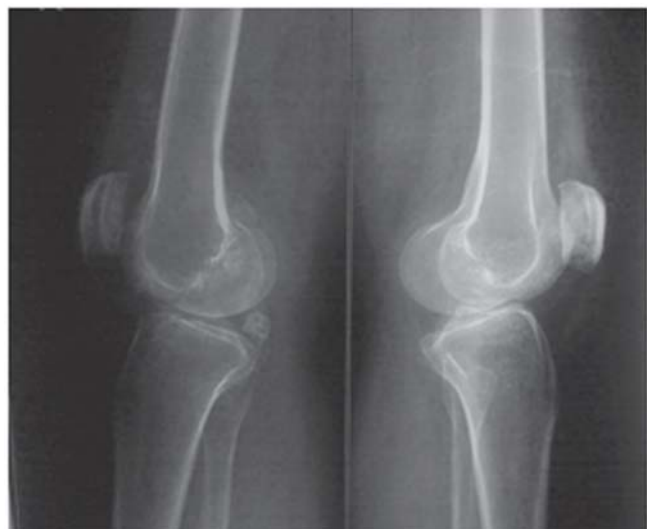

Fig: 4

Author's affiliations

¹ MD, MRCP(UK), Assistant Professor, Dept. of PMR, IPGMER & SSKM Hospital, Kolkata.

² MD, Associate Professor, Dept. of PMR, BSMC, West Bengal

Initially a provisional diagnosis of osteo-arthritis of knee joint was made and base line investigations like inflammatory markers and x-rays were advised. Initial rehabilitative management like joint protection, life style

modification, exercise regimen and paracetamol 1g four times a day was started. According to her blood reports Hb% 10g/dl (69%), WBC- 10,200 (neutrophil 68%, lymphocyte 27%), ESR 56, fasting blood glucose 90g/dl, creatinine 0.9, TSH 5.8. Considering significantly disproportionate involvement of right knee joint one diagnostic synovial fluid aspiration was done. The synovial fluid was inflammatory in nature without any Gram-stain response, AFB, malignant cell and crystals. Her x-rays findings are shown in Figs 3 & 4.

Interestingly we noticed lots of opacities in x-rays, looking like loose bodies due to osteo-arthritis of knee. But few

spots are located little bit proximally (eg, superior lateral side of right knee). After a careful observation we were sure that these were unlikely to be in the suprapatellar pouch. At this juncture a MRI scan of knee was advised due these unexplained lesions.

In MRI scan Figs 5–8 multiple focal calcifications were seen in peri and retro-articular region with such lesion also seen along the margins of the condyle. The MRI was reported as a case of synovial chondromatosis which is a benign but rare clinical condition of knee joint. Subsequently the patient was referred to department of orthopaedics for surgical excision.

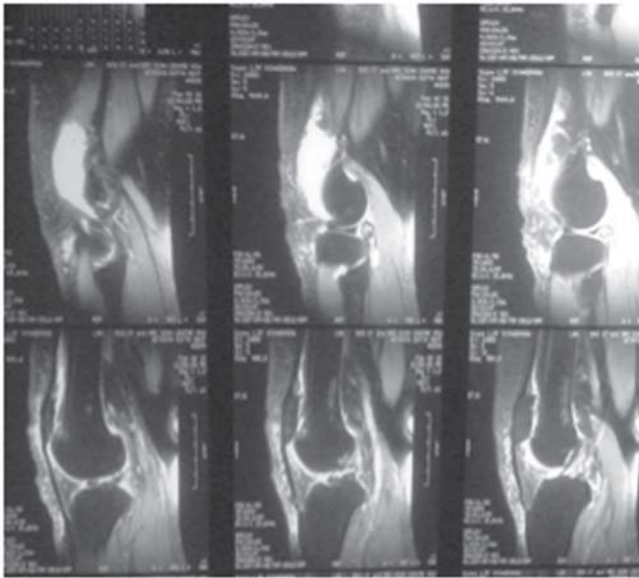


Fig: 5

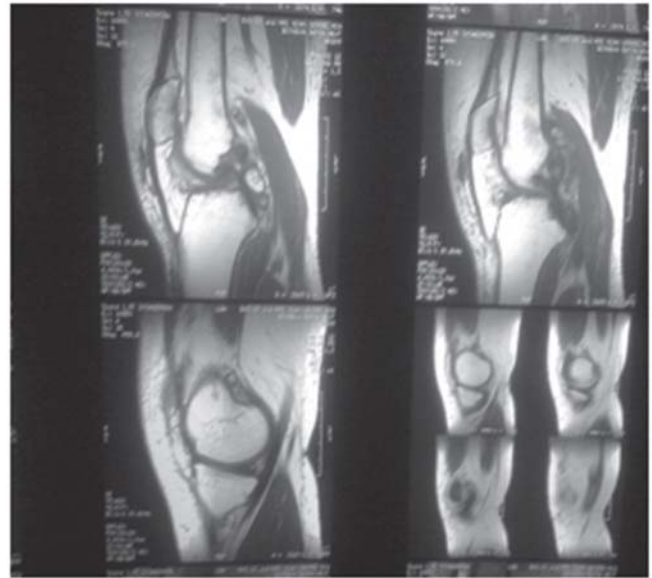


Fig: 6

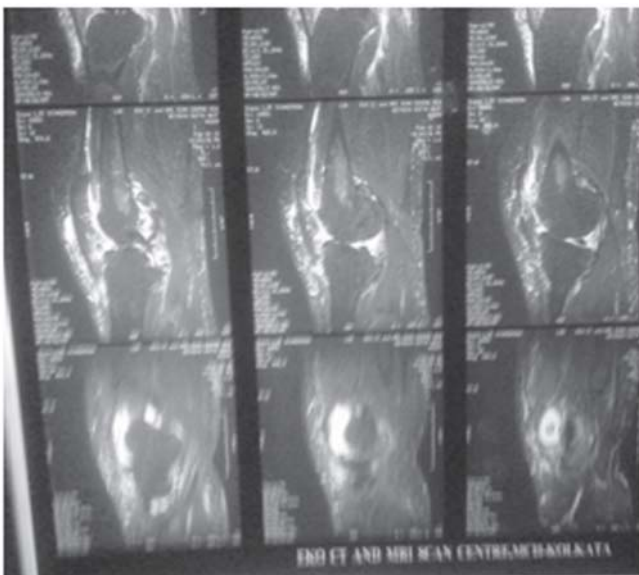

Fig: 7

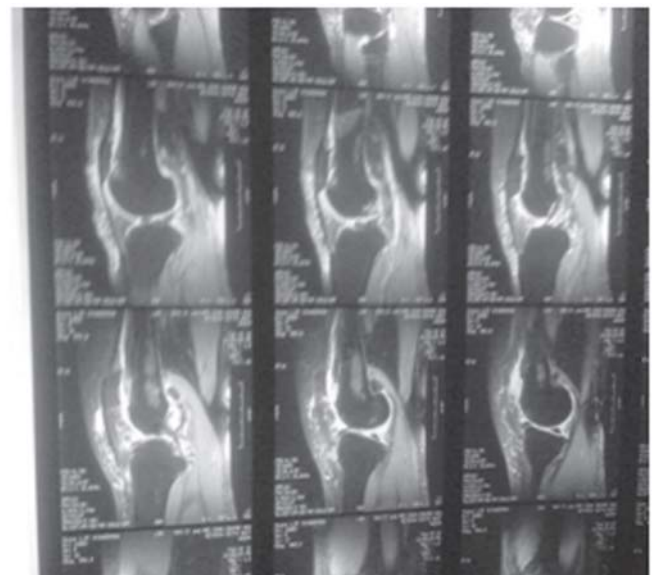


Fig: 8