

Arnold Chiari Malformation with Holocord Syringomyelia Presenting as Unilateral Foot Drop: A Case Report

Krishnaprasad I.N¹, Soumya V², Abdulgafoor S³

Abstract

Foot drop is a common problem encountered in the clinical practice of a medical rehabilitation specialist. The aetiology of foot drop is usually lower motor neuron, either by the affection of peripheral nerve or the lower lumbar roots. However other rare differential diagnosis of foot drop should be borne in mind while evaluating such a patient. A detailed neurological evaluation along with supportive investigations like electrodiagnosis and magnetic resonance imaging often helps in differentiating such a cause. Here we report a case of holocord syringomyelia, secondary to Arnold Chiari malformation type 1, presented as unilateral foot drop.

Key words : Foot drop, syringomyelia, Arnold Chiari malformation.

Introduction:

Foot drop is defined as a weakness on foot dorsiflexion, usually caused by lower motor neuron (LMN) disease. Common causes are L4-L5 radiculopathy, caused by either an intervertebral disc prolapse or foraminal stenosis, and peroneal neuropathy. Other causes include any axonal or demyelinating damage along the whole peripheral nervous system: lower spinal cord, cauda equina, lumbar plexus, and peripheral mixed nerve. Central nervous system pathology can also cause foot drop¹. Central causes tend to occur where nerve fibres are highly condensed along the UMN tracts: motor cortex, corona radiata, internal capsule, cerebral peduncle, medulla, and spinal cord pyramidal tract. We present a young patient with insidious onset of unilateral foot drop caused by an extensive spinal pathology.

Case Report:

A five-year-old female child, apparently normally developed for age, presented with some difficulty in walking for the past eight months. The complaints started as difficulty in getting the right foot to the toe box of shoes and sandals, for which she needs assistance of her mother. The difficulty later progressed into walking difficulty with occasional pain in the leg and tripping on right foot while walking. She didn't have similar complaints in the left foot and also didn't have any motor or sensory symptoms in both upper limbs. She had recurrent episodes of posterior neck and head pain, which caused only mild functional impairment. For the past six months symptoms were constant. She didn't complain of any bladder symptoms, visual complaints, swallowing or speech difficulty. There was no history of trauma to the right leg before the onset of symptoms. There was nothing relevant in her past history except for a few episodes of febrile seizures which subsided spontaneously two years back. There was also no relevant family history of similar neurological illnesses. The child was fully immunised up to her age.

On examination, height and weight were adequate for age, no pallor or generalised lymphadenopathy, no skin lesions, and vitals were within normal limits. Right thoracolumbar scoliosis (Fig 1) was present, which persisted on Adams forward bending test. No limb length discrepancy noted. On right lower limb the motor power was grade 4 proximally, and grade 3 minus on ankle dorsiflexors. However plantar flexors showed grade 4

Author's affiliations:

¹MD, DNB, MNAMS (PMR), Assistant Professor

²MBBS, MD (PGT), Junior resident

³MD, DPMR, Professor and Head
Government medical college, Kozhikode, Kerala

Cite as:

Krishnaprasad IN, Soumya V, Abdulgafoor S. Arnold Chiari Malformation with Holocord Syringomyelia Presenting As Unilateral Foot Drop: A Case Report. IJPMR September 2012; Vol 23 (3): 123-6.

Correspondence:

Dr Krishnaprasad IN (Main author), Assistant Professor, Government medical college, Kozhikode, Kerala, Email: doctorkris79@gmail.com

Received on 24/07/2012, Accepted on 01/10/2012

power. Left lower limb and both upper limbs showed grade 5 power. Deep tendon reflexes were normally elicitable from all four limbs, except right ankle jerk which was sluggish. Plantar reflex was not elicitable on right side. Mild wasting of hypothenar muscles and mild clubbing were noticed on both hands (Fig 2). Grip was moderate and appropriate for her age. There were no sensory findings in all four limbs or trunk. Cranial nerves and cerebellar function tests were within normal limits.

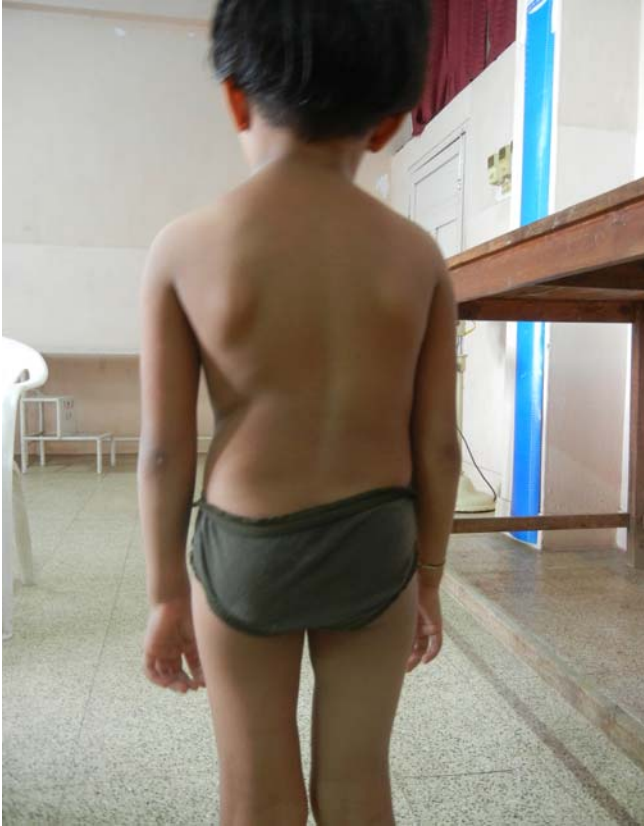

Fig 1- Thoracolumbar Scoliosis

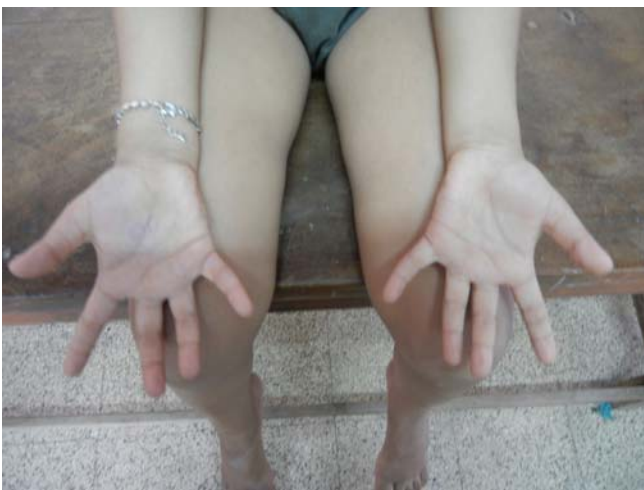

Fig 2- Wasting of Hypothenar Muscle

Nerve conduction study was performed in all four limbs. CMAP and SNAP were recorded from median, ulnar, radial, peroneal, tibial and sural nerves. Bilateral median CMAP and SNAP were found to be within normal limits. Low amplitude CMAPs were recorded from both ulnar nerves suggestive of an axonal loss pattern, whereas corresponding SNAPs were within normal limits. Both tibial CMAPs were within normal limits. Low amplitude axonal loss pattern was recorded from both peroneal nerve CMAPs, with normal SNAPs. Sural SNAP also recorded normally. F waves were either absent or latency prolonged from all motor nerves suggested. The whole NCS picture pointed towards an anterior horn cell involvement, and further work up with MRI was planned. X-ray of spine (Fig 3) showed thoracolumbar scoliosis towards right with apex at T12 and absent rotation. Cobb's angle measured was 30 degrees. No other abnormalities were detected.

MRI of the spine (Fig 4) with post contrast enhancement showed extensive syringohydromyelia involving the

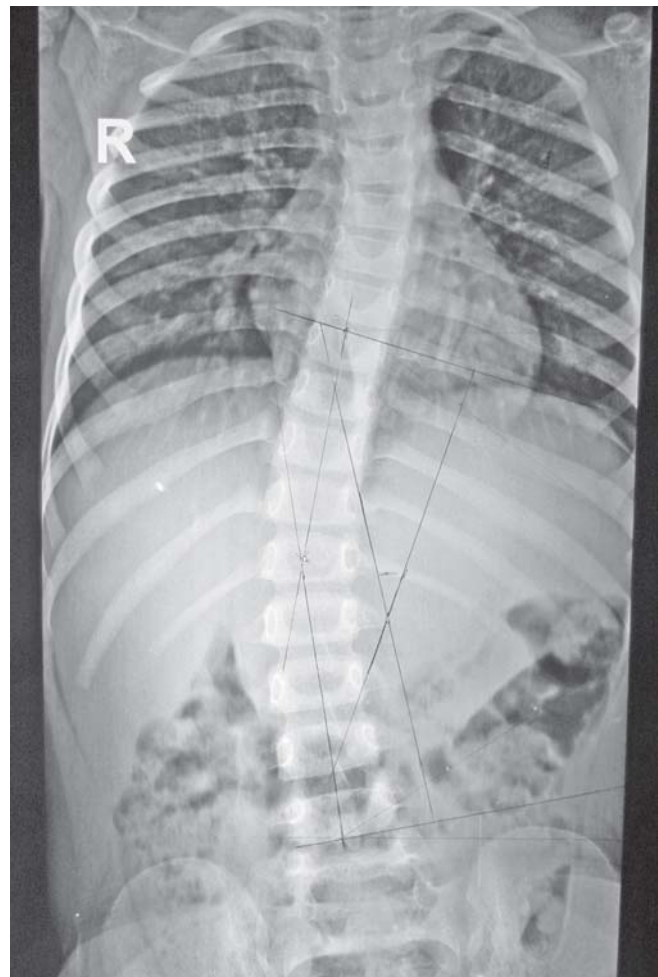


Fig 3- Straight X-ray Showing Scoliosis

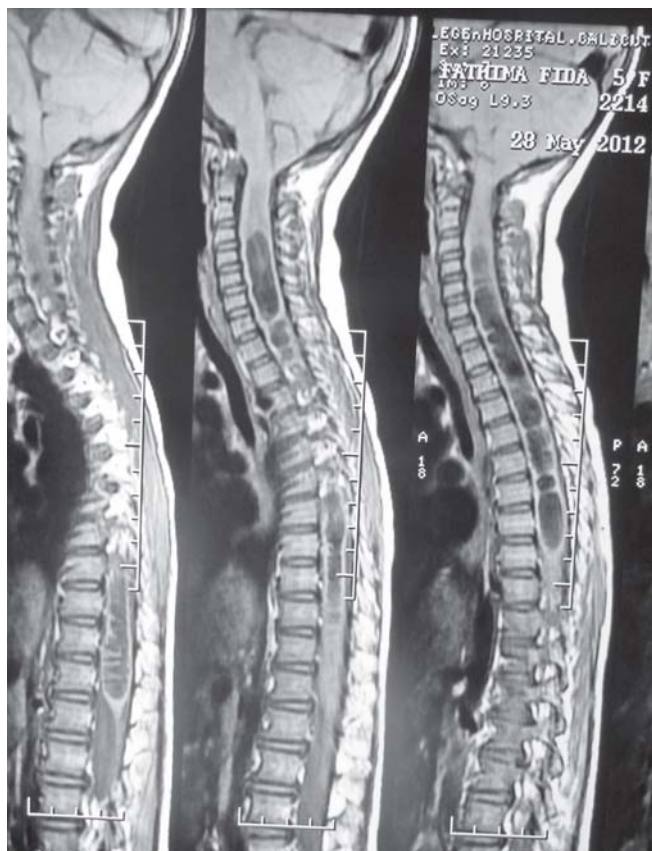

Fig 4- MRI Showing Involvement of Spinal Cord

entire cord from C2 to T10 with no abnormal contrast enhancement. Herniation of cerebellar tonsils noted 4 mm below foramen magnum. The findings were consistent with Arnold Chiari malformation type 1.

Discussion:

Syrinxes associated with congenital foramen magnum encroachment (Chiari malformations) may result from either central canal dilation (i.e., communicating syringomyelia or hydromyelia) or from an eccentric syrinx cavity in the gray matter of the cord (non-communicating syringomyelia). Because the two types of syrinxes are often indistinguishable by imaging studies, particularly later in the disease, they may be referred to as syringohydromyelia or hydrosyringomyelia.

Chiari I malformation is a congenital downward displacement of the cerebellar tonsils through the foramen magnum, into the cervical subarachnoid space. Chiari II malformation is downward displacement of the cerebellar vermis, pons, and medulla into the foramen magnum and elongation of the fourth ventricle. Chiari I malformation typically presents clinically in young

adults, whereas Chiari II malformation presents in infants and is usually associated with myelomeningocele and hydrocephalus. Chiari I malformation is the most common cause of syringomyelia. Although it usually presents clinically in young adult years, it may manifest first in an infant or older adult. The duration from onset of symptoms to diagnosis is typically 3 to 7 years.

The earliest symptom is often headache or neck or arm pain aggravated by straining or coughs; neck pain may be accompanied by torticollis. Neurologic findings depend on the structures involved. The syrinx is often noted at the C4–6 bony levels but may extend rostrally or caudally the full length of the cord (holocord syringomyelia). Dissociated sensory loss in a cape like distribution over the neck and arms is characteristic, because crossing spinothalamic tract fibres carrying pain and temperature sensation are most affected, whereas posterior column sensory fibres are spared. Hand and arm weakness develop as lower motor neurons of the cervical cord are affected. Long-tract myelopathic symptoms develop in the lower limbs with further expansion of the cervical syrinx.

Worsening scoliosis is common, particularly in childhood-onset syringomyelia of Chiari I malformation. Other associated craniocervical abnormalities like Klippel–Feil anomaly (congenital fusion of cervical vertebrae) and atlanto-occipital assimilation may coexist. Syrinx extension into the brainstem can lead to lower cranial nerve, cerebellar and respiratory problems. Rostral or caudal extension of the syrinx may result from rapid changes in intraspinal pressure, such as those caused by coughing, straining, or sneezing.

Chiari II malformation often presents in infancy as stridor, weak cry, nystagmus, and apnoea or in childhood as gait abnormality, spasms, worsening incoordination, and nystagmus. Later, it may lead to loss of head control, arm weakness, spasms, and tetraparesis.

Differential diagnosis for syringomyelia of Chiari I malformation includes multiple sclerosis; spinal muscular atrophy, amyotrophic lateral sclerosis; spinocerebellar ataxias, cervical disc and post-traumatic syringomyelia from trauma, arteriovenous malformation, arachnoiditis or meningitis, neurofibromatosis, and from spinal cord or brainstem tumours.

MRI confirms the diagnosis, but asymptomatic tonsillar herniation is common. Because cerebellar tonsils retract upward with age, MRI interpretation depends on age-appropriate controls. Tonsillar herniations greater than

6 mm are significant up to age 10 (In our patient it was 4 mm), greater than 5 mm for ages 10 to 30, and greater than 4 mm for ages over 30. However, 30 per cent of persons with cerebellar herniations of 5 to 10 mm are asymptomatic.

Treatment of Chiari I malformation involves posterior fossa decompression with a suboccipital craniectomy, with or without dural patch grafting, and cervical laminectomy with fenestration or shunting of the syrinx cavity. In patients with mild symptoms, 70 to 80 per cent report improvement. Some authors² suggest that direct surgery of the syrinx should be undertaken only after craniocervical decompression has failed.

A “top-down” approach has been suggested for surgical treatment of Chiari II malformation: shunt for hydrocephalus, then posterior fossa decompression for Chiari malformation, then syringopleural shunt for syringomyelia if needed.

After posterior decompression, with or without syrinx shunting, 50 per cent or more patients improve; in those with syrinxes, about one-third improves, one-third stabilises, and one-third deteriorates further after surgery. Postoperative neurologic decline can result from recurrent syringomyelia, occipital C1–C2 instability, pseudomeningocele, tethering of the spinal cord, meningitis, and extradural abscess.

Conclusion:

Bilateral progressive foot drop as a manifestation of holocord syringomyelia has been reported in the literature³⁻⁵. In all those reports, however there were other manifestations of typical syringomyelia which helped in differentiating the condition. In our patient, despite extensive spinal involvement the manifestations are limited to scattered motor findings and scoliosis.

Other prominent feature of syringomyelia, the dissociated sensory loss, was conspicuously absent and inexplicable. Since nerve conduction studies showed evidence of moderate axonal loss in the CMAPs from peroneal and ulnar nerves bilaterally with abnormality in F waves, a pathology involving the anterior horn cells was suspected. Those findings along with the presence of scoliosis, prompted us to do a spinal work up with MRI which helped us to establish the diagnosis. This case stresses the importance of conducting a comprehensive clinical examination, ably supported by appropriate investigations, in any patient presenting with a seemingly peripheral lesion.

We took a neurosurgery opinion for the child for any surgical intervention. But since the clinical features were static at present and child was not significantly disabled, it was decided to manage conservatively at present, and consider decompression only if clinical worsening observed on follow-up. The child was given an ankle foot orthosis to aid ambulation and a molded spinal jacket to prevent spinal curve progression, and is currently under active follow-up.

References:

1. Westhout FD, Pare´ LS, Linskey ME. Central causes of foot drop: rare and underappreciated differential diagnoses. *J Spinal Cord Med* 2007; **30**: 62-6.
2. Little JW. Syringomyelia. Lin VW, Cardenas DD In: editor Spinal Cord Medicine: Principles and Practice. New York; 2003: 504-5.
3. Muhn N, Baker SK, Hollenberg RD, Meaney BF, Tarnopolsky MA. Syringomyelia presenting as rapidly progressive foot drop. *J Clin Neuromuscular Disord* 2002; **3**: 133-4.
4. J Kumar, A Kumar, S Gupta. Chiari I malformation with holocord syrinx. *J Neurol Neurosurg Psychiatry* 2007; **78**: 146.
5. Saifudheen K, Jose J, Gafoor VA. Holocord syringomyelia presenting as rapidly progressive foot drop. *J Neurosci Rural Pract* 2011; **2**: 195-6.