

# Mucopolysaccharidosis and Rehabilitation

Harshanand P<sup>1</sup>, Anil Kumar G<sup>2</sup>, Vivek P<sup>3</sup>, Jayasree R<sup>4</sup>

### Abstract

Mucopolysaccharidosis is a rare lysosomal storage disorder with overall prevalence of all types is 3.53 per 100,000 live births. Exact figures are not available for Indian population. It has poor prognosis with no easy curative medical or surgical management. This case report describes two cases of mucopolysaccharidosis with type one and type four variant. These cases diagnosed and rehabilitated to increase quality of life. Early identification of such cases by clinical features, supportive investigations and rehabilitation management can help patient to improve functional independence and activities of daily living.

**Key words:** Mucopolysaccharidosis, Rehabilitation.

### Introduction:

The mucopolysaccharidoses (MPSs) are a family of metabolic disorders caused by the deficiency of lysosomal enzymes needed to degrade glycosaminoglycan (GAG)<sup>1</sup>. GAG is an important constituent of the extracellular matrix, joint fluid, and connective tissue throughout the body. Progressive accumulation of GAG within the cells of various organs ultimately compromises their function. The overall prevalence of all types of MPSs is 5.53 per 1,00,000 live births<sup>2</sup>.

### Case 1:

A 10 year old male child came to PMR OPD with chief complaints of dysmorphic facial features since birth and regression of milestones. It was associated with decreased vision and intelligence. There was history of

consanguineous marriage (first degree). He was operated 2 years back for umbilical hernia. On clinical examination, more abdominal girth, mild hepatosplenomegaly, and mild cardiomegaly were present. CNS examination: Higher function- speech and intelligence is moderately impaired with long term memory loss. Cranial nerve examination, vision is impaired due to corneal clouding. Motor examination showed power of all muscles was 3/5. Reflexes of upper and lower extremities were brisk with Babinski reflex positive. Musculoskeletal examination showed characteristic facial appearance (Fig 1) which includes macrocephaly, bossing of forehead, proptosis of both eyes, corneal clouding, low set ears, flattening of nose bridge, macroglossia, widening of teeth, short neck, short chest, kyphoscoliotic deformity with convex curve towards right side, widening of metaphysis at elbow, wrist, knee and ankle seen. Both hands showed short phalanges. Range of motion at shoulder, hip restricted bilaterally. Elbow and knee range of motion showed fixed flexion deformity of 20 degree. On functional evaluation child was having good sitting balance, he was unable to do all routine activities of daily living like eating brushing, grooming, clothing and toileting because of deformity. On gait analysis; he walks with support to both hands, hip and knee in flexion, ankle with foot in dorsiflexion. Patient was investigated with radiographs. Radiographs of skull (Fig 2) showed anteroposterior diameter more than lateral, 'J' shaped sella tursica, premature fusion of sutures, and widened mandibular angle, dorsolumbar spine (Fig 3) showed kyphosis, lumbar vertebrae showed anteroinferior beaking with posterior scalloping. Ribs

#### Author's affiliation:

<sup>1</sup>MBBS, MD (PGT) Junior Resident

<sup>2</sup>MBBS, DPMR, DNB (PMR), Professor and Head of Department

<sup>3</sup>MBBS, MS (ORTHOPEDIC), Specialist Grade 1

<sup>4</sup>MBBS, DNB (PMR) Assistant Professor

AIIPMR Mumbai

#### Cite as:

Harshanand P, Anil Kumar G, Vivek P, Jayasree R. Mucopolysaccharidosis and rehabilitation. *IJPMR* June 2013; Vol **24**(2): 44-7.

#### Correspondence:

Dr Harshanand Popalwar (main author), Junior Resident, All India Institute of Physical Medicine and Rehabilitation, Mahalaxmi, near Haji Ali Park, Mumbai 400034.

E mail : harshanand.popalwar@gmail.com

Received on 25/12/2012, Revised on 25/09/2013

Accepted on 03/10/2013

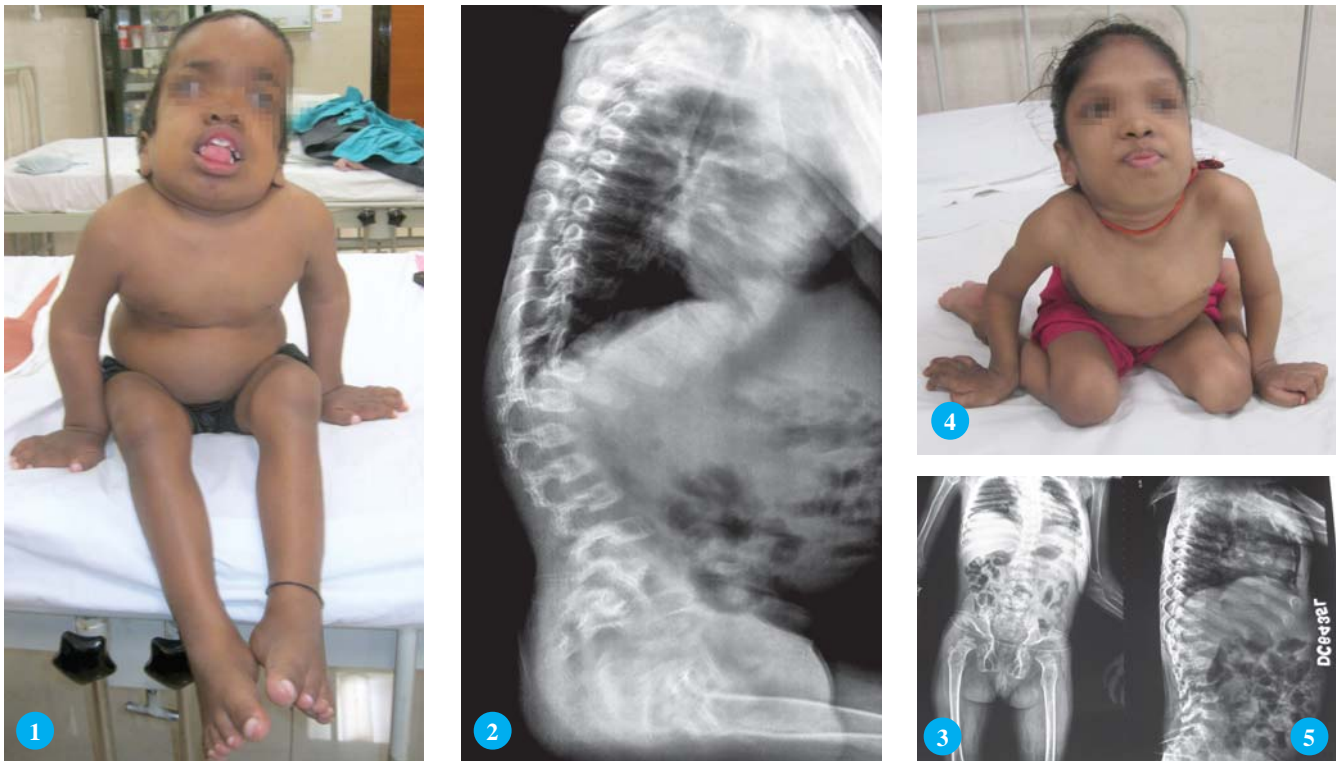
were wide and paddle shaped. Radiographs of elbow and hand showed widened diaphysis of long bones with osteoporosis and cortical thinning, subluxation of proximal radioulnar joints, proximal tapering of metacarpals with short and broad phalanges. Radiographs of knee showed bilateral medial bowing of lower end of femur. Urine analysis for screening of mucopolysaccharidosis was positive. Blood examination for typing/ deficiency of enzyme of mucopolysaccharidosis done and it is positive for alpha-L-iduronidase. By clinical examination and biochemistry, diagnosis of mucopolysaccharidosis type 1 (Hurler syndrome) confirmed.

### Case 2:

A 8-year-old female child came to PMR OPD with chief complaint of inability to walk with prominences of bones of upper and lower extremity. She started difficulty in walking with prominence of wrist, elbow and knee bones from 2nd year. She developed weakness of neck and back muscles producing neck hyperextension and kyphoscoliotic deformity at back. Symptoms were progressing slowly. She lost walking and routine activities of daily living like eating, brushing, grooming etc, since last one

year. On clinical examination, cardiovascular system showed mild cardiomegaly. Central nervous system: Higher functions were normal. Power was generalised 3/5. Musculoskeletal examination: Facial features included macrocephaly, bluish tinge of sclera, high arched palate, short neck with poor stability or control, (Fig 4) prominent chest ribs, prominent elbow, wrist joints, knee in genu valgum deformity, prominence of knee joint bones. Joints were hypermobile with excess range of motion at wrist extension, hip extension, internal and external rotation, and ankle joint dorsiflexion.

Radiographs of skull showed similar findings with case one. Radiograph of cervical spine showed odontoid hypoplasia. Radiograph of thoracolumbar spine (Fig 5) showed kyphoscoliosis with anterior beaking of lumbar vertebrae. Radiograph of radius and ulna showed similar findings with case one. Screening of urine for mucopolysaccharides ie. glycos-amino-glycans (GAG) done. Report came positive for mucopolysaccharidosis. Two dimensional electrophoresis of 24 hours urine for typing of mucopolysaccharidosis has been done. Report positive for mucopolysaccharidosis type 3 with advice of clinicopathological correlation. The diagnosis of mucopolysaccharidosis should be confirmed by direct



**Fig 1-** Showing Characteristic Facial Expression; **Fig 2-** Straight X-ray Skull Showing Anteroposterior Diameter more than Lateral; **Fig 3-** Straight X-ray Showing Dorsolumbar Kyphosis; **Fig 4-** Showing Facial Feature; **Fig 5-** Thoracolumbar Spine Showing Kyphoscoliosis

enzymatic assay in leucocytes or fibroblasts. These tests were not available in India. After clinicopatho-radiological correlation, diagnosis of mucopolysaccharidosis type 4 (Morquio syndrome) has been drawn.

In consideration of availability of medical management (enzyme replacement therapy in india) post surgical complications and life expectancy of bone marrow transplantation<sup>3</sup>, rehab management is more significant and helpful to improve quality of life of patient.

### Rehabilitation Management:

Counselling of parents about prognosis of the disease done. Genetic screening of parents and other siblings were advised.

Problems list for both cases

1. Generalised weakness of all muscles, dependent ambulation, activities of daily living, transfers and toileting.
2. Poor head control, kyphoscoliotic deformity at back and impaired sitting balance
3. For case one; Impairment of vision due to corneal clouding

### Rehabilitation:

Submaximal strengthening exercises of all muscles of body, stretching exercises and deep breathing exercises has been given to prevent contractures and increase vital capacity of lung.

- Night splints have been given to prevent further occurrence of deformity at knee and elbow. Cervical collar have been given for cervical instability and its future complication to both cases. Standard wheelchair with neck support has been given in consideration of future progress of disease. Patient has been trained for activities of daily living with minimal assistance of care giver.
- For case one, as kyphoscoliotic deformity is correctable, posterior shell total contact thoracolumbar orthosis with lateral extension with anterior ring and straps given. Rationale behind giving anterior ring and straps was to prevent chest expansion and respiratory compromise due to orthosis in future. For case two, total contact thoracolumbar orthosis correcting scoliosis with anterior straps has been given.
- For case 2, wrist joint stabilisation of right side done by below elbow cock up splint for finger movement and to increase grip strength. Left side resting hand splint given.

- Patient has been taught transfers from wheelchair to bed/commode and vice versa.
- For case one, Ophthalmology consultation done for decreased vision and advised cataract surgery.
- For case one, special school for mentally challenged has been advised. For case two, normal school has been advised.
- The WEE FIM scoring before and after six months of rehabilitation done. It is depicted in Table 1.

### Discussion:

Mucopolysaccharidosis was first described by Charles Hunter, a Canadian physician. Mucopolysaccharidosis type I (MPS I) Hurler syndrome is an autosomal recessive disorder caused by deficiency of  $\alpha$ -L-iduronidase. Mucopolysaccharidosis type I have incidences of 0.69 per 100,000 live births<sup>3</sup>. Characteristic clinical features which differentiate it from other types include early onset of disease, dysmorphic facial features, corneal clouding, mental retardation, umbilical or inguinal hernia, and dysostosis multiplexa. All these clinical features were present in case one. Morquio syndrome (Type 4) incidence: Internationally; the estimated incidence covers a wide range, including 1 case per 75,000 births in Northern Ireland, 1 case per 200,000 births in British Columbia, and 1 case per 263,157 births in Germany<sup>4</sup>.

Medical management is based on principle of enzyme replacement therapy. Some US based pharmaceutical companies came with new drug known as Aldurazyme<sup>®</sup> (Iaronidase)<sup>5</sup>. It is the first enzyme replacement therapy drug to specifically treat the underlying cause of MPS I. It is prescribed for people with Hurler and Hurler-Scheie forms of MPS I and for people with the Scheie form who have moderate to severe symptoms. The main problem with treatment of Iaronidase is anaphylaxis and related complications. This drug is not available in India. No enzyme replacement therapy available for Morquio syndrome. Vellodi *et al*<sup>3</sup> did study on life expectance post bone marrow transplantation of MPS 1 patients and shows that average duration of life expectancy is 3 years with recurrent bone marrow transplantation.

Very few publications are available about rehabilitation management of mucopolysaccharidosis. Gulati and Agin<sup>6</sup> (1996) studied Morquio syndrome: a rehabilitation perspective. They described rehabilitation of Morquio patients post quadriplegia due to odontoid hypoplasia. Because of odontoid dysplasia, spinal cord compression occurs which leads to tetraplegia or quadriplegia. This

**Table 1:** Showing Wee Firm Score before and after Rehabilitation

| Area                     |                                   | Case One              |                      | Case Two              |                      |
|--------------------------|-----------------------------------|-----------------------|----------------------|-----------------------|----------------------|
|                          |                                   | Before rehabilitation | After rehabilitation | Before rehabilitation | After rehabilitation |
| <b>Self care</b>         | 1. Eating                         | 1                     | 6                    | 1                     | 6                    |
|                          | 2. Grooming                       | 1                     | 6                    | 2                     | 4                    |
|                          | 3. Bathing                        | 1                     | 5                    | 2                     | 4                    |
|                          | 4. Dressing– Upper Body           | 1                     | 5                    | 2                     | 6                    |
|                          | 5. Dressing– Lower Body           | 1                     | 5                    | 2                     | 6                    |
| <b>Sphincter control</b> | 6. Toileting                      | 7                     | 7                    | 7                     | 7                    |
|                          | 7. Bladder management             | 7                     | 7                    | 7                     | 7                    |
|                          | 8. Bowel management               | 7                     | 7                    | 7                     | 7                    |
| <b>Transfers</b>         | 9. Transfers:Bed/Chair/Wheelchair | 1                     | 4                    | 1                     | 4                    |
|                          | 10. Transfers: Toilet             | 3                     | 4                    | 1                     | 4                    |
|                          | 11. Transfers: Bath/Shower        | 3                     | 5                    | 1                     | 4                    |
|                          | 12. Walk/Wheelchair               | 1                     | 6                    | 1                     | 4                    |
|                          | 13. Locomotion: Stairs            | 1                     | 1                    | 1                     | 1                    |
| <b>Communication</b>     | 14. Comprehension                 | 7                     | 7                    | 7                     | 7                    |
|                          | 15. Expression                    | 7                     | 7                    | 7                     | 7                    |
| <b>Social cognition</b>  | 16. Social interaction            | 7                     | 7                    | 7                     | 7                    |
|                          | 17. Problem solving               | 3                     | 3                    | 7                     | 7                    |
|                          | 18. Memory                        | 3                     | 3                    | 7                     | 7                    |
| <b>WeeFIM® Total</b>     |                                   | 72                    | 96                   | 70                    | 99                   |

article describes rehabilitation of quadriplegic patients of Morquio syndrome.

### Conclusion:

The prognosis of Hurler syndrome is poor with average life expectancy for Hurler syndrome is first decade. Death mostly occurs due to respiratory failure. Early diagnosis of patients with appropriate rehabilitation can improve functional independence and activities of daily living.

### References:

1. Yano S, Moseley K, Pavlova Z. Postmortem studies on a patient with mucopolysaccharidosis type I: histopathological findings after one year of enzyme replacement therapy. *J Inherit Metab Dis* 2009; [Medline].
2. Baehner F, Schmiedeskamp C, Krummenaver F, Miebach E, Baiboui M. Cumulative incidence rate of mucopolysaccharidoses in Germany. *J Inherit Metab Dis* 2005; **28**: 1011-7.
3. Vellodi A, Young EP, Cooper A, Wraith JE, Winchester B, Meaney C, Ramaswami U. Bone marrow transplantation for mucopolysaccharidosis type I: experience of two British Centres. *Arch Dis Child* 1997; **76**: 92-9
4. Braverman NE, Buehler B. Genetics of mucopolysaccharidosis Type 4 (<http://emedicine.medscape.com/article/947254>)
5. [http://www.aldurazyme.com/pt/treat/az\\_us\\_pt\\_about.asp](http://www.aldurazyme.com/pt/treat/az_us_pt_about.asp)
6. Gulati MS, Agin MA. Morquio syndrome: a rehabilitation perspective. *J Spinal Cord Med* 1996; **19**: 12-6.